

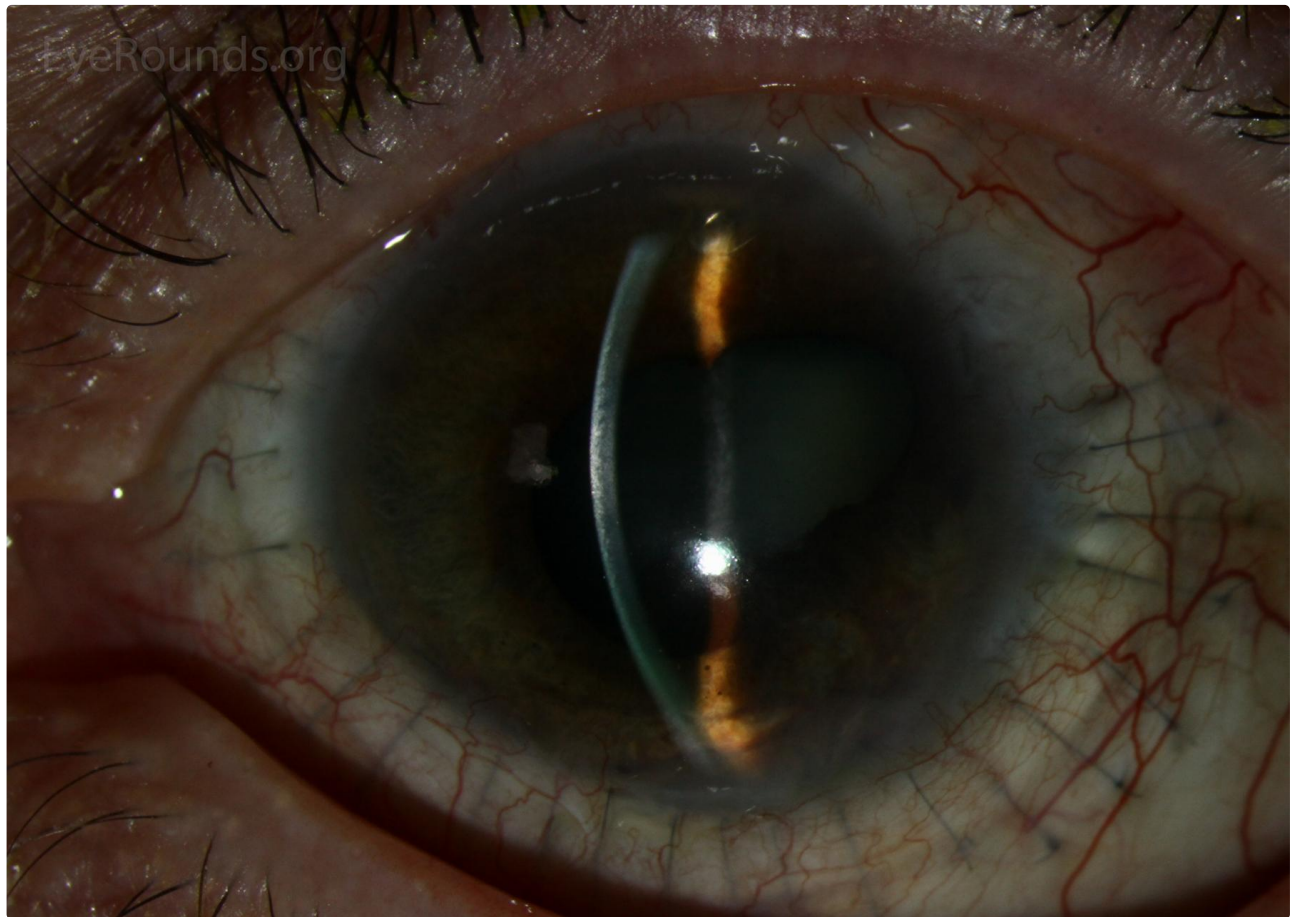
## Penetrating sclerokeratoplasty

Category(ies): Cornea

Contributor: [Jesse Vislisel, MD](#)

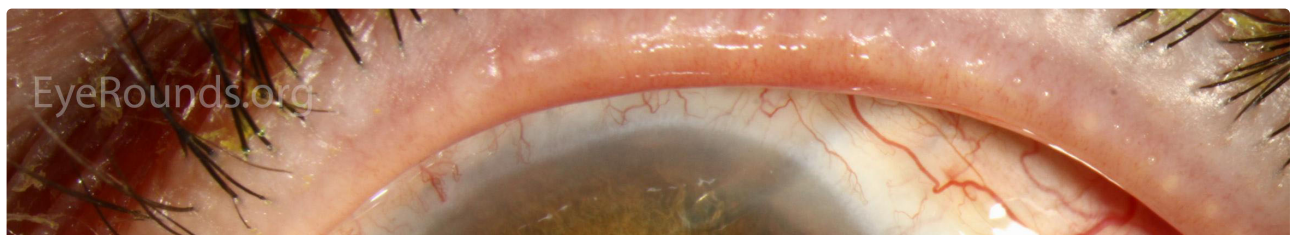Photographer: Carol Chan, CRA

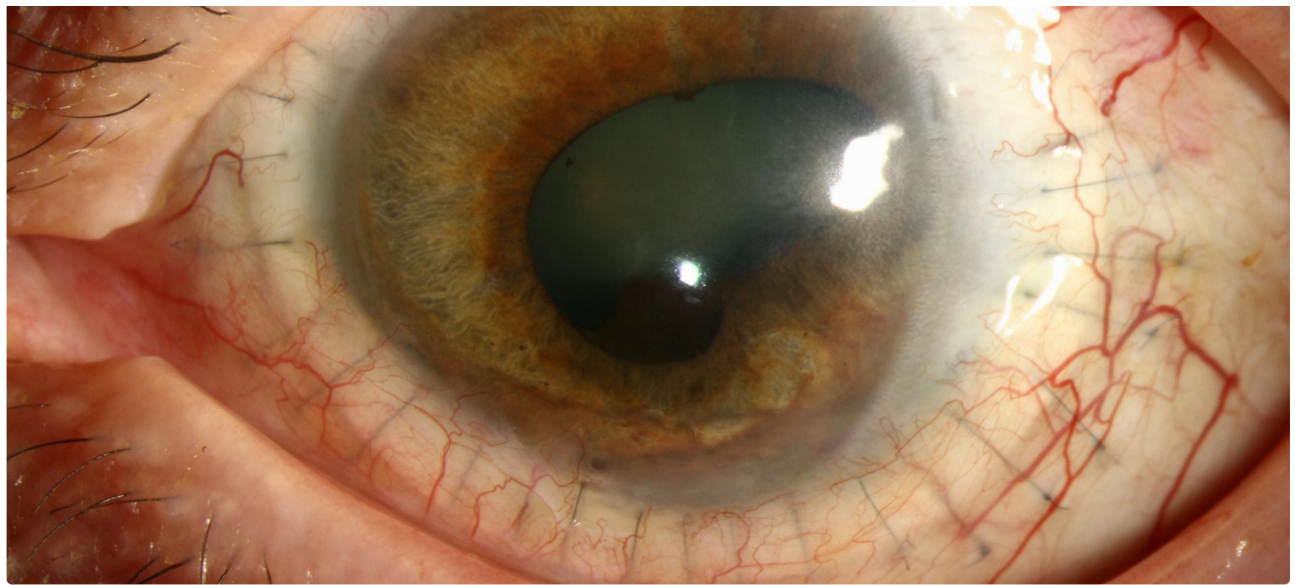
Penetrating sclerokeratoplasty involves the transplantation of the entire cornea and adjacent scleral rim. This patient underwent the procedure for refractory acanthamoeba sclerokeratitis. The sutures holding the graft in place can be seen in the sclera around the graft. The pupillary margin is irregular secondary to central posterior synechiae from intraocular inflammation secondary to the infection. A glaucoma seton is visible in the anterior chamber superonasally.



 Enlarge

 Download





[Enlarge](#)

[Download](#)

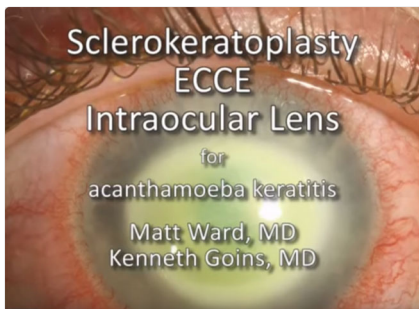
### Image Permissions:



Ophthalmic Atlas Images by [EyeRounds.org](#), [The University of Iowa](#) are licensed under a [Creative Commons Attribution-NonCommercial-NoDerivs 3.0 Unported License](#).



### Related Articles



[Related Surgical Video:  
Sclerokeratoplasty, ECCE, and  
Intraocular lens for Acanthamoeba  
Keratitis](#)

### Address

University of Iowa  
Roy J. and Lucille A. Carver College  
of Medicine  
Department of Ophthalmology and

### Legal

Copyright © 2019 The University of  
Iowa. All Rights Reserved  
[Report an issue with this page](#)

### Related Links

[Cataract Surgery for Greenhorns](#)  
[EyeTransillumination](#)  
[Gonioscopy.org](#)

### EyeRounds Social Media

[Follow](#)

Visual Sciences  
200 Hawkins Drive  
Iowa City, IA 52242

[Support Us](#)

[Web Privacy Policy](#) |  
[Nondiscrimination Statement](#)

[Iowa Glaucoma Curriculum](#)  
[Iowa Wet Lab](#)  
[Patient Information](#)  
[Stone Rounds](#)  
[The Best Hits Bookshelf](#)



[Receive notification of new cases,  
sign up here](#)  
[Contact Us](#)  
[Submit a Suggestion](#)